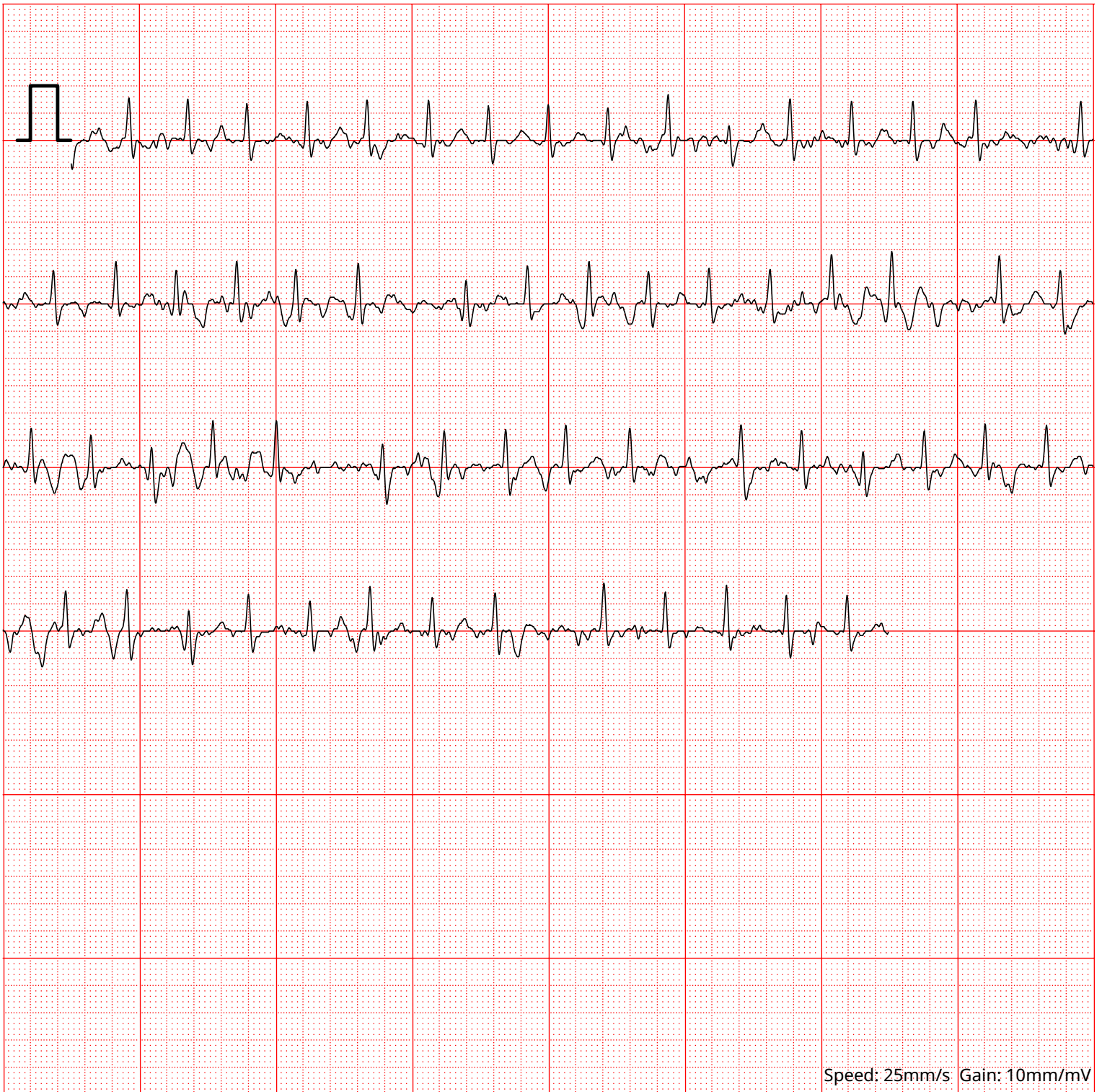


EMAY ECG Report

User: vincent, Male, 75yrs
Recorded Time: Jan 5, 2026 1:39:42 PM
Duration: 30s

Heart Rate: 123 bpm
Leads: 1
Result: Possible - Tachycardia



Remark: